

Type: Poster Presentation

Final Abstract Number: 41.226

Session: Poster Session I

Date: Thursday, March 3, 2016

Time: 12:45–14:15

Room: Hall 3 (Posters & Exhibition)

Campylobacter jejuni infection and Guillain-Barré syndrome: An emerging cause of acute flaccid paralysis after the eradication of poliomyelitis in BangladeshZ. Islam^{1,*}, M.B. Islam¹, B.C. Jacobs², I. Jahan¹, Q.D. Mohammad³, H.P. Endtz²¹ International Centre for Diarrhoeal Disease Research, (icddr), Dhaka, Bangladesh, Dhaka, Bangladesh² Erasmus University Medical Centre, Rotterdam, The Netherlands, Rotterdam, Netherlands³ National Institute of Neurosciences and Hospital, Sher-e-Bangla Nagar, Agargaon, Dhaka, Dhaka, Bangladesh

Background: Bangladesh has achieved a remarkable success with the eradication of poliomyelitis. However, non-polio acute flaccid paralysis and its clinical presentation as the Guillain-Barré syndrome (GBS) is still frequently diagnosed. GBS has a diverse clinical phenotype that varies according to geography. *Campylobacter jejuni* enteritis is the predominant bacterial infection preceding GBS. The purpose of the study was to define the clinical phenotype of GBS and the relation with preceding *C. jejuni* infection and anti-ganglioside antibodies (GM1, GD1 and GQ1b) in a large GBS cohort from Bangladesh.

Methods & Materials: We conducted a hospital based observational study including 403 patients fulfilling the National Institute of Neurological Disorders and stroke (NINDS) criteria for GBS patients between 2010 and 2013 in Dhaka Medical College Hospital, Dhaka, Bangladesh. Detailed clinical, electrophysiological, serologic and microbiological data were obtained.

Results: GBS affected predominantly in young adults males (M/F=2:1) living in rural areas. Antecedent events were recorded in 76% of patients. The most frequent events being gastroenteritis (46%) and upper respiratory tract infection (18%). Sixty-five percent of the patients were bed-bound (Hugh's F-score, 4) at entry and 17% patients required mechanical ventilator (F-score 5). Electrophysiological studies showed that 54% of patients had an axonal variant of GBS. About 90% patients did not receive specific treatment either Intravenous Immunoglobulin (IVIg) or plasmapheresis due to high expensive treatment cost. After 6 months follow up, 13% patients had died and 15% were still disabled. Evidence for a recent *C. jejuni* infection was found in 55% of GBS patients. In a GBS-associated strains collection from Bangladesh, capsular types HS23/36c, HS19, and HS41 were most prevalent. MLST analysis showed that HS19 (ST-22), HS23 (ST-3219) and HS41 (ST-362) were prevalent. Anti-ganglioside antibodies (GM1, GD1a and GQ1b) were frequently detected in GBS patients.

Conclusion: GBS in Bangladesh is a severe, predominantly pure motor and axonal neuropathy with a high mortality rate. Recent *C. jejuni* infection and anti-ganglioside antibodies accounted for a significant proportion of GBS. Majority of the patients do not receive specific and standard treatment with IVIg in view of its high price. Therefore, low-cost treatment strategies are required for GBS patients in developing countries.

<http://dx.doi.org/10.1016/j.ijid.2016.02.414>**Type: Poster Presentation**

Final Abstract Number: 41.227

Session: Poster Session I

Date: Thursday, March 3, 2016

Time: 12:45–14:15

Room: Hall 3 (Posters & Exhibition)

Dengue sero-prevalence and serotype distribution among children near Hyderabad, IndiaG.R. Jammy^{1,*}, E. Ganguly², G. Oruganti², S. Garg³, A. Bhavsar⁴, J. Nealon⁵¹ Graduate School of Public Health, University of Pittsburgh, Pittsburgh, USA² SHARE INDIA, Medciti Institute of Medical Sciences, Ghanpur, Hyderabad, India³ Maulana Azad Medical College, New Delhi, India⁴ Sanofi Pasteur, Mumbai, India⁵ Sanofi Pasteur, Singapore, Singapore

Background: India has reported cases of dengue for more than 200 years and in recent times this has burdened the healthcare system and challenged policy makers. It is estimated that dengue is substantially under reported, a fact corroborated by seroprevalence finding 50 – 89% of adults have suffered at least one infection in their lifetime. Younger age is a risk factor for severe disease and in recent outbreaks, many cases have been observed in children. Co-circulation of multiple serotypes is also a risk for severe disease and the relationships between serotypes, attack rate and susceptibility are important to inform prevention and control activities, including vaccination.

Methods & Materials: A community-based, cross-sectional, seroprevalence study (CTRI/2011/12/002243) was conducted at 8 sites in India among apparently healthy 5–10 year old children from January 2011 to 2012. This analysis was conducted to improve understanding of dengue epidemiological parameters and environmental and demographic covariates from 2 sites located in southern India near Hyderabad. Dengue was tested by Indirect enzyme-linked immunosorbent assays (ELISA) and positive samples were subject to PRNT₅₀ to detect neutralizing antibodies against DENV-1, DENV-2, DENV-3 and/or DENV-4.

Results: The mean age of 640 subjects included in the analysis was 7.8 years. Dengue IgG seroprevalence was 58.3% (373 subjects with previous exposure and increased with age. Of PRNT profiles, 190 (50.9%) were multitypic, signifying >1 previous infection, 170 (45.6%) were monotypic, and 13 (3.5%) were seronegative. DENV2 & DENV3 predominated (29.5% and 40.0% of multitypic; and 41.8% and 27.6% of monotypic profiles), however, serological profiles against all four serotypes were identified. Serological outcome was not affected by sex, piped water supply to house, public sewer presence, water storage in house, previous dengue infection and family history of dengue infection.

Conclusion: The levels of previous exposure, the quantum and increasing trends with age and multiple serotypes circulating among children <11 years of age indicate transmission potency and risk of severe disease episodes following secondary infections, even in young children.

There is an urgent need for appropriate interventions to control, diagnose and treat dengue, more sensitive public health surveillance and further research to identify the covariates in dengue disease.

<http://dx.doi.org/10.1016/j.ijid.2016.02.415>

Type: Poster Presentation

Final Abstract Number: 41.228

Session: Poster Session I

Date: Thursday, March 3, 2016

Time: 12:45-14:15

Room: Hall 3 (Posters & Exhibition)

Human ocular dirofilariasis due to *Dirofilaria repens*: an underdiagnosed entity or emerging filarial disease?



L.G. Jessani^{1,*}, S. Patil², D. Annapurneshwari², S. Durairajan³, R. Gopalakrishnan⁴

¹ Apollo Hospital, Chennai, Chennai, Tamil Nadu, India

² Apollo Hospital, Chennai, Chennai, India

³ Apollo Hospitals, Chennai, India

⁴ Apollo Hospital, Chennai, India

Background: *Dirofilaria* are natural filarial parasites of dogs, cats and foxes. Human dirofilariasis is an accidental zoonotic infection caused by species *Dirofilaria* such as *D.immitis*, *D.tenuis* and *D.repens*. Human ocular dirofilariasis were initially reported from Kerala. But for a solitary case of oral dirofilariasis, it has not been reported from Tamil Nadu. We report a case of subcutaneous human dirofilariasis of the eyelid in a 37 years old woman caused by *D. repens*.

Methods & Materials: A 37 year old female from urban Chennai with no co-morbidities presented with painless swelling of one month in the right eyelid which had a waxing/waning course. No other ocular or systemic features. No history of animal exposure. Ocular swelling was soft, cystic, non tender. Blood counts were normal with no eosinophilia. Provisional clinico-radiological diagnosis of epidermoid cyst or lacrimal adenitis was made and she underwent excision of lesion. Macroscopic examination revealed soft tissue grey-brown mass. Microscopic examination revealed eosinophils and fragments of adult nematode. Outer surface of the nematode's cuticle revealed longitudinal beaded ridges and transverse striations and was identified as *D. repens* which was confirmed by CDC. Microfilaraemia and filarial antigen test was negative. She was treated with ivermectin and diethylcarbamazine.

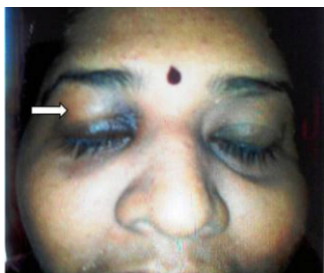

fig 1

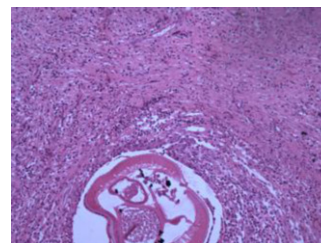
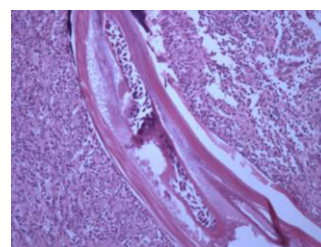


fig 2



Results: Subcutaneous dirofilariasis is mostly caused by *D. repens* in Asia. Patients usually present with inflammatory subcutaneous masses containing increased numbers of eosinophils, which may or may not be tender. Ophthalmic involvement may be periorbital, subconjunctival, or intraocular. Eosinophilia is not usually present. Diagnosis of dirofilariasis in humans remains difficult as the symptoms exhibited by the patient are varying and nonspecific depending upon the location of worm. Identification of the worm in biopsy confirms diagnosis. Chemotherapeutic agents appear to be ineffective. Surgical removal of the worm is the treatment of choice

Conclusion: A number of cases of human dirofilariasis from areas other than Kerala are being reported. Distribution of human cases of dirofilariasis seems to mirror the distribution of canine cases. Whether there a true increase in cases or were they earlier under reported, undiagnosed or unidentified due lack of awareness among the treating clinicians needs to be determined to know the actual prevalence.

<http://dx.doi.org/10.1016/j.ijid.2016.02.416>

Type: Poster Presentation

Final Abstract Number: 41.229

Session: Poster Session I

Date: Thursday, March 3, 2016

Time: 12:45-14:15

Room: Hall 3 (Posters & Exhibition)

Clinical profile and serological epidemiology of scrub typhus and spotted fever among hospitalized children at a tertiary hospital in South India



B.S. Kalal^{1,*}, P. Puranik², S. Nagaraj¹, S. Rego², A. Shet²

¹ St. John's Medical College Hospital, Bangalore, Karnataka, India

² St. John's Medical College Hospital, Bangalore, India

Background: Scrub typhus, a re-emerging rickettsial disease caused by *Orientia tsutsugamushi*, is an important cause of febrile illness in the Asia-Pacific region. The present study was undertaken